

# Adeno Carcinoma - Pancreas

---

## Peri ampullary Ca-Pancreas & Chronic Cholecystitis

**Mr. M. R. K. Age 46yrs.**

Peri ampullary Ca-Pancreas & Chronic Cholecystitis

Status before approaching SEARCH Homoeopathic Cancer Care Centre

8/2/1999 -Hospitalized - for Pruritus due to Chole-lithiasis. (Gallstones)

16/3/99 -Re hospitalization for - Chronic Cholecystitis

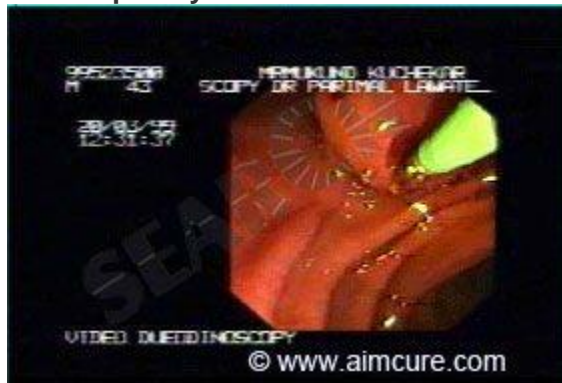## Investigations

17/3/99 - USG Abd.- Small Gall Bladder calculi, No evidence of Cholecystitis, Dilatation of proximal CBD & intra hepatic biliary radicles.

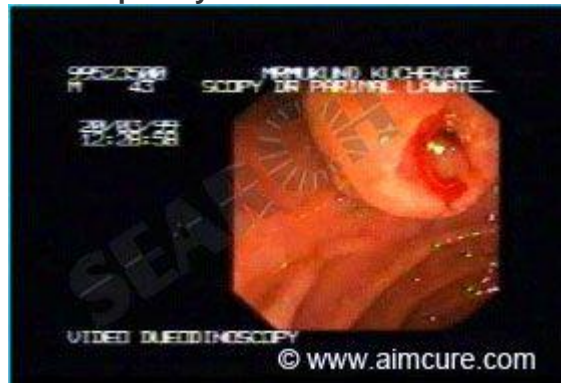
19/3/99- Multiple Gallstones, Dilated Intra & Extra Hepatic biliary radicles, with a suspicion of distal CBD iso dense Calculus, Pancreas appears Normal.

20/3/99 - Gastro Scopy - Peri ampullary Growth. Biopsy taken

### Peri Ampullary Growth



### Peri Ampullary Growth



24/3/99 - Whipple's Procedure done under General Anesthesia.

27/3/99 - Histopathology Report - Chronic Cholecystitis, Marked Cholelithiasis Papillary Peri ampullary Adeno Carcinoma.

19/4/99 -Patient was Discharged with Drain in Situ Pouring about 400cc / day.

Homoeopathic Treatment Started - 15/5/99

Patient Presented with

1. Drain pouring about 150cc/day, Discharge, Offensive+++
2. Severe Prostration, Anorexia +++
3. Wt loss 10 kg in last 2 months
4. Prolapsed infected & thrombosed Piles with intolerable pain & burning.
5. Acute - Abdominal Colic & Gaseous Distension.

## **With in 30 minutes - Colic reduced**

After 7 days- Infection of the wound Controlled, Offensiveness & oozing reduced gradually & Stopped within 5 to 6 days after starting homoeopathic treatment.

24/5/99 - Drain was removed. Follow-up USG Abd - H/o Whipple's noted for Ampullary Malignancy, Otherwise Within Normal Limits

## **PERFORMANCE SCORE- 40**

24/6/1999 - Abdominal pains with flatulence reduced, Appetite increased, Pain & P/R bleeding reduced, General prostration + FEELING OF WELL-BEING ESTABLISHED

7/7/1999 - Feeling of well being continued... All his complaints were reducing gradually. Wt. gain - 4kg.since last 2 months. (From 71 to 75 kg)

12/7/1999 - Epididymo orchitis (new C/o) rest improving gradually.

## **PERFORMANCE SCORE-70**

27/7/99- Orchitis reduced, Bleeding from anus, Pain increased, Fatigue++, Constipation & flatulence restarted, But all these C/o were much lesser in intensity than beginning.

5/8/99-All C/o reduced, (epididymo orchitis as well as Chief complaints )

13/9/99- Till last month had fluctuations in C/o, But now He is almost Asymptomatic

## **PERFORMANCE SCORE-90**

16/5/2000- Was Observed (Only on Placebo Therapy) for next 6 months.

Was Absolutely Asymptomatic PERFORMANCE SCORE-100

## **Investigations**

3/7/2000- (Jehangir Hospital Reports ) X-RAY CHEST - Nothing abnormal detected USG Abdomen - No intra abdominal spread or local recurrence of the past pancreatic pathology. ADVISED NO TREATMENT

## **Re-investigated After 2 Years**

7/5/2002- X-ray Chest, USG Abdomen - Normal Expert -Dr.N.J.Nayak.

## **Re-investigated After 4 Years**

6/1/2004 - USG-Abdomen, Endoscopy - Normal Expert -Dr.N.J.Nayak.